

Review article

# Angelman syndrome: is there a characteristic EEG?<sup>☆</sup>

Laura A.E.M. Laan\*, Alla A. Vein

*Department of Neurology and Clinical Neurophysiology, Leiden University Medical Center, P.O. Box 9600, 2300 RC Leiden, The Netherlands*

Received 14 July 2003; received in revised form 22 September 2003; accepted 23 September 2003

## Abstract

Angelman syndrome (AS) is a genetic disorder characterised by severe mental retardation, subtle dysmorphic facial features, a characteristic behavioural phenotype, epileptic seizures and EEG abnormalities. AS can be caused by various genetic mechanisms involving the chromosome 15q11–13 region. Neurophysiological studies report a variety of EEG abnormalities seen in AS patients. The objective of this article was to analyse whether there are characteristic EEG changes in AS, whether this varies with age and what the differential diagnosis is. Most of the authors agree about the existence of three main EEG patterns in AS which may appear in isolation or in various combinations in the same patient. The pattern most frequently observed both in children and in adults has prolonged runs of high amplitude rhythmic 2–3 Hz activity predominantly over the frontal regions with superimposed interictal epileptiform discharges. High amplitude rhythmic 4–6 Hz activity, prominent in the occipital regions, with spikes, which can be facilitated by eye closure, is often seen in children under the age of 12 years. There is no difference in EEG findings in AS patients with or without epileptic seizures. AS patients with a deletion of chromosome 15q11–13 have more prominent EEG abnormalities than patients with other genetic disturbances of the chromosome 15 region. The EEG findings are characteristic of AS when seen in the appropriate clinical context and can help to identify AS patients at an early age when genetic counselling may be particularly important.

© 2004 Elsevier B.V. All rights reserved.

*Keywords:* Angelman syndrome; EEG; Epileptic seizures; Differential diagnosis

## 1. Introduction

In 1965, the first description of Angelman syndrome (AS) was reported by Harry Angelman, an English paediatrician [1]. He described three severely mentally retarded children with similar facial features, absence of speech, paroxysms of laughter, abnormal puppet-like gait, epileptic seizures, and an abnormal EEG. For more than 20 years, AS was considered to be a rare disorder but now it is clear that the clinical spectrum is much broader than was originally thought [2,3]. AS is caused by different genetic mechanisms involving the chromosome 15q11–13 region varying from maternal deletion, paternal uniparental disomy, imprinting defects and point mutations or small deletions within the UBE3A gene, which lies within this region [3]. To date, AS can be genetically confirmed in 85–90% of patients clinically diagnosed as having this disorder. The incidence of AS is estimated to be between 1 in 10,000 and 1 in 40,000

[3]. Neurophysiological studies report a variety of EEG abnormalities in AS patients [4–8]. It is fascinating to note that EEGs of AS patients (in contrast to many other epilepsies with infantile onset such as West syndrome, Lennox-Gastaut syndrome, and others) do not have a standard paradigm of abnormalities with regard to both the background activity and the epileptiform discharges in the same patient [4,9]. Moreover, changes in EEG abnormalities with age mean that one unified neurophysiological pattern for AS patients cannot be found [9]. Nevertheless, epileptic seizures in combination with suggestive EEG abnormalities are indispensable for reaching an early diagnosis of AS and providing appropriate genetic counselling.

In this article, we want to discuss three topics. Is there a characteristic AS EEG? Is there variability with age and what is the differential diagnosis?

## 2. Is there a characteristic Angelman EEG?

The EEG abnormalities of AS children were originally described by Boyd et al. and later confirmed and worked out

<sup>☆</sup> The paper is based on the lecture given at the Sixth Annual Meeting of the Infantile Seizure Society, Tokyo, March 15–16, 2003.

\* Corresponding author. Tel.: +31-71-5262134; fax: +31-71-5248253.  
E-mail address: [l.a.e.m.laan.neurology@lumc.nl](mailto:l.a.e.m.laan.neurology@lumc.nl) (L.A.E.M. Laan).

by other authors [4–11]. An abnormal EEG is often seen in AS patients from at least 1 year of age [4]. The prevalence of EEG abnormalities seen in AS children and adults is about 80% [4,9]. All EEG abnormalities seen in AS patients can be divided into three main EEG patterns:

1. Persistent rhythmic 4–6 Hz activity, exceeding 200  $\mu$ V, often generalised, not associated with drowsiness and persisting for a large part of the recording (Fig. 1). There is no blocking effect due to eye closure, something, which could be fairly specific for AS, because rhythmic theta activity seen in other syndromes happens to disappear on eye closure. This pattern can be seen in AS patients under the age of 12 years [4,6,9].
2. This is described as the most frequently occurring pattern in the known series of AS patients both in children and adults [4,6,7,9–11]. It is characterised by rhythmic delta activity of 2–3 Hz (200–500  $\mu$ V) often more prominent in the anterior regions with the superimposed interictal epileptiform discharges in the form of spikes and sharp waves, sometimes reminiscent of spike–wave complexes (Fig. 2). The epileptiform activity has a moderate amplitude and a multifocal distribution. Slow activity tends to be generalised and to be predominant over the epileptiform activity [6]. Laan et al. have described a variation in this pattern as an intermittent or sometimes continuous run of rhythmic triphasic 2–3 Hz activity of high amplitude (200–500  $\mu$ V), mixed with spikes or sharp waves with a maximum over the frontal regions [9]. This pattern was found in almost 50% of AS patients before the clinical diagnosis AS was made. The triphasic waves in AS differ from the ‘typical’ triphasic waves observed in metabolic diseases. Although triphasic waves are fairly recurrent EEG features in adulthood, they have not been reported in children [12]. Most of the observed patients with triphasic waves had an altered consciousness including coma, while the runs of the triphasic waves in AS are for the most part seen in alert and responsive patients [9]. Another peculiarity of the triphasic waves in AS patients is a lack of reactivity, not the same as the triphasic activity known to disappear during sleep [13].
3. The third EEG pattern consists of spikes and sharp waves mixed with 3–4 Hz components of high amplitude, usually exceeding 200  $\mu$ V, mainly posteriorly and facilitated by, or only seen on eye closure [4] (Fig. 3). The EEG abnormalities in the posterior regions were the most frequent findings in the series of young children reported by Casara et al. [7]. This observation could not be confirmed by Laan et al. because it was very difficult to perform the eye-closure test in these hyperactive and severely retarded children [9]. We know that AS patients have severe sleep problems with frequent waking. The EEG abnormalities are reported not only in the awake but also in the sleeping state.

Polysomnography during spontaneous sleep showed no phasic sleep organisation in children [4,14]. The runs of slow and sharp waves become continuous during stage 2 sleep and disappear or reduce during rapid eye movement sleep [10]. On the whole sleep disturbances are frequently reported in AS, and they are often associated with increased motor activity during sleep, arousals, awakenings and reduced total sleep time [15].

There is no difference in EEG findings in AS patients with or without epileptic seizures [8,9,14]. No correlation was found between any particular EEG pattern and the paroxysms of laughter although one author has mentioned diffuse 2–3 Hz high voltage slow wave bursts without spike discharges [4,11]. There is a constellation of EEG features in AS which may appear in isolation or in various combinations either on the same occasion or at different times in the same patient [4,9]. Guerrini et al. studied the rhythmic myoclonus in AS, mainly involving hands and face, and found that this was accompanied by short bursts of rhythmic 5–10 Hz EEG activity [16].

### 2.1. EEG phenotype and genotype correlation

The correlations between the genetic disorders and EEG abnormalities were analysed. There are only few publications on this subject. EEG abnormalities are much more prominent in AS patients with a deletion (97–100%) and not so pronounced in those with other genetic disturbances (UBE3A mutation, uniparental disomy, methylation disturbances [9,10] [Table 1]). In the studies of Matsumoto et al. [6] and Minassian et al. [10] all patients with large chromosome 15q11–13 deletions had distinct EEG abnormalities of slow and a disorganised background rhythm in combination with bursts of slow (2–3 Hz) triphasic waves or spike waves. On the other hand, a normal awake EEG background rhythm was reported in 72.2% of AS patients with uniparental disomy, methylation imprinting abnormalities and UBE3A mutations [10]. Laan et al. found EEG abnormalities in 35 of 36 AS patients with a chromosome 15q11–13 deletion in which the child without EEG abnormalities was only 10 weeks old. Abnormal EEG patterns were found in 6 of 8 patients with UBE3A mutations [17,18].

The EEG abnormalities found in AS patients are not themselves pathognomonic of AS and have to be seen in the appropriate clinical context. There are, however, some characteristic EEG abnormalities that are mainly seen in AS. First of all, the pattern with prolonged runs of high amplitude rhythmic 2–3 Hz activity spread predominantly over the anterior regions with the superimposed interictal epileptiform discharges. This is rarely reported in other disorders, while other patterns can be observed in a broad spectrum of infantile disorders. Secondly, the EEG abnormalities in AS are persistent, relatively independent of the waking-sleep cycle and do not disappear on a simple

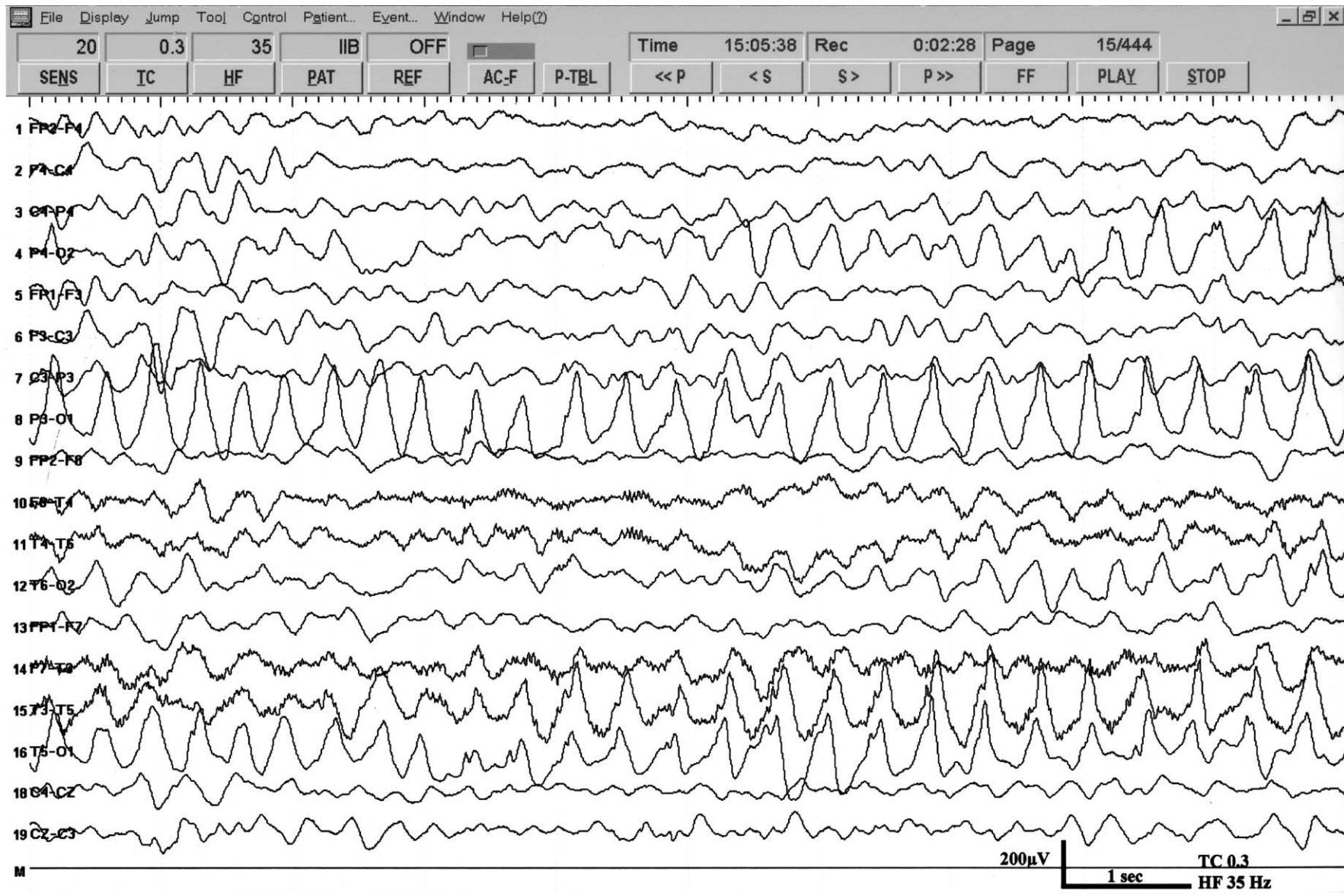


Fig. 1. Persistent rhythmic 3–4 Hz activity in a 16-month-old boy with AS and a proven deletion of chromosome 15q11–13.

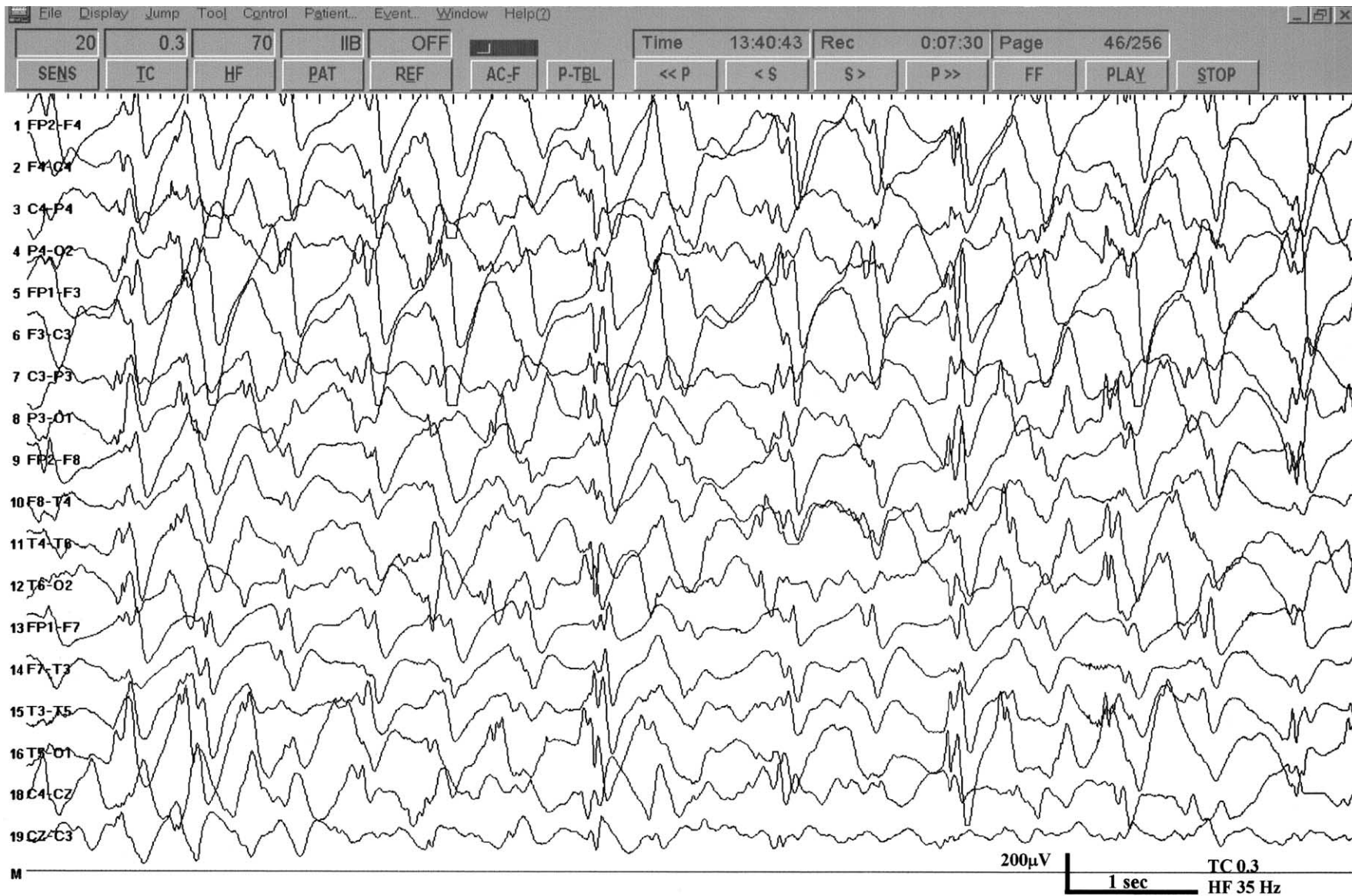


Fig. 2. Rhythmic 2 Hz activity (triphasic activity) most prominent over the frontal regions, mixed with spikes and sharp waves, in a 4-year-old boy with AS and a proven deletion of chromosome 15q11-13.

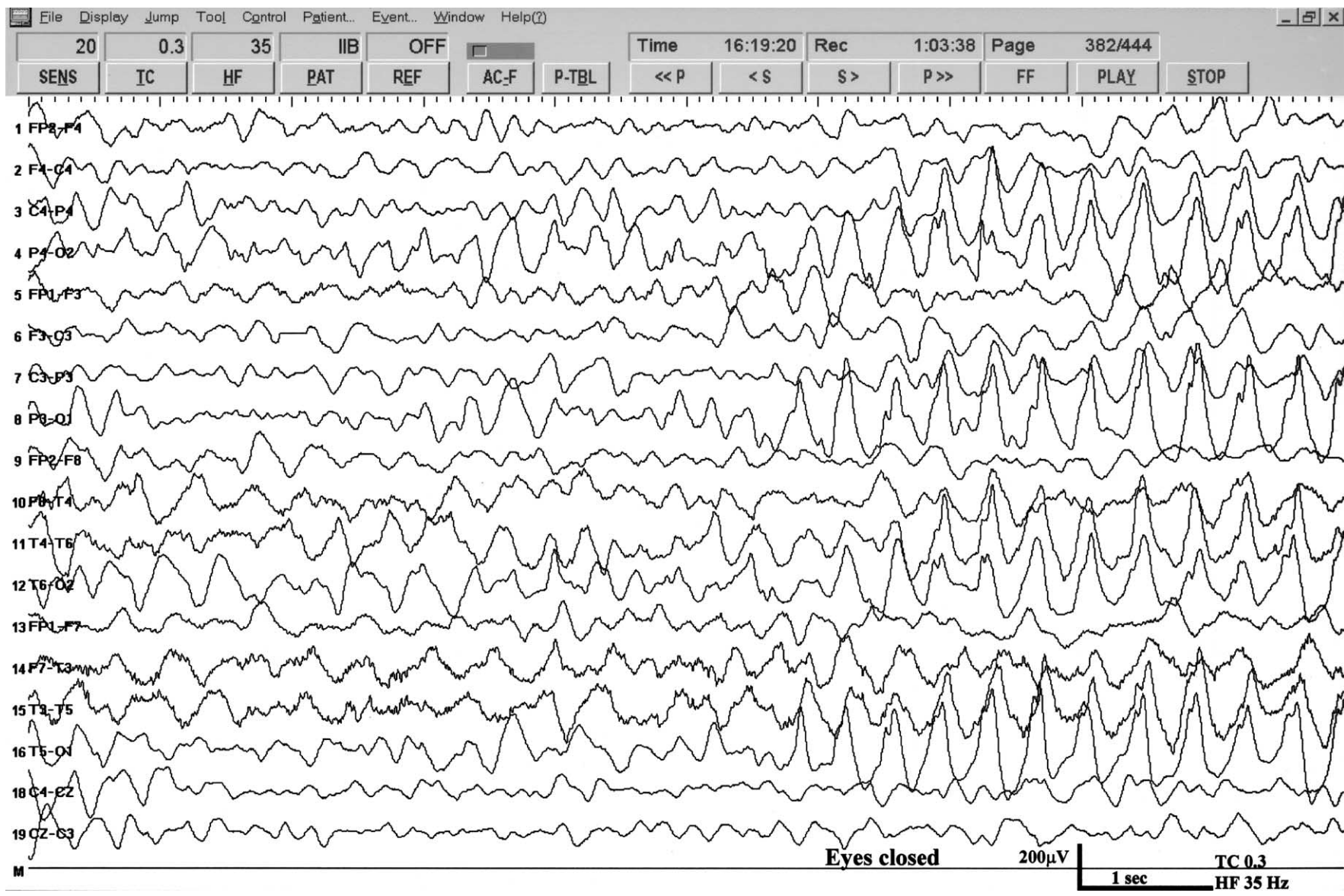


Fig. 3. Spikes and sharp waves mixed with 3–4 Hz components of high amplitude, mainly posteriorly and facilitated on eye closure, in the same AS patient as in Fig. 1.

Table 1  
EEG abnormalities and genetic disorders in Angelman syndrome patients

	Deletion	UBE3A mutation	Uniparental disomy	Methylation imprinting abnormalities
Minassian et al. [10]	9 patients: 9/9 EEG abnormalities as described by AS	2 patients: 2/2 normal EEG background and 2/2 slow spike waves, one of them in sleep	4 patients: 3/4 normal EEG background and 3/4 bursts of slow spike waves	5 patients: 3/5 normal EEG background and 4/5 bursts of slow spike waves
Laan et al. [9,17,18]	36 patients: 35/36 EEG abnormalities as described by AS <sup>a</sup>	8 patients: 6/8 EEG abnormalities as described by AS		
Matsumoto et al. [6]	8 patients: 8/8 EEG abnormalities as described by AS			

<sup>a</sup> The AS patient without EEG abnormalities was age 10 weeks.

stimulus such as eye closure. These features might be helpful in differentiating AS EEG from other EEGs in severely retarded patients with or without epileptic seizures.

The EEG features of AS appear to be sufficiently characteristic to help identify AS patients at an early age before clinical features become obvious and at a time when genetic counselling may be particularly important.

### 3. Is there a variability with age?

Evolution of EEGs in AS in childhood has been examined by several authors [6–9,14]. The EEG abnormalities occur very early, usually in the first 2 years of life, and often precede the clinical manifestations of AS [4,9]. In some cases, these EEG patterns are not found. In practice, it may be necessary to carry out more EEG examinations before one finds this pattern, but there are patients who do not demonstrate these EEG abnormalities, although the clinician might be considering the possibility of this syndrome. Exact data about this item are not available although it is the personal experience of several experts [4,9].

The younger the AS child, the more florid the EEG abnormalities are, with at least two of the above-mentioned EEG patterns [4,6,9]. The EEG abnormalities gradually change from (1) high voltage, slow burst activity (1–3 Hz), mixed with 4–6 Hz activity of high amplitude in the very young children (more evident in children under the age of 4 years) to (2) 4–6 Hz activity over the posterior regions, mixed with spikes and spike–wave activity in children up to puberty, to (3) a background rhythm which is too slow for age, sometimes mixed with focal or multifocal spikes, in the adult patients [6–10,14]. There was a perception that the characteristic EEG pattern of rhythmic 2–3 Hz activity of high amplitude over the frontal regions, often continuously present in childhood, did not occur in adults [3,4]. Laan et al. reported that most AS patients, irrespective of their age, demonstrated EEG abnormalities in the form of prolonged runs in childhood of rhythmic triphasic 2–3 Hz activity with

high amplitude and a maximum over the frontal regions mixed with spikes or sharp waves, although this often changes to intermittent runs of this type of activity in adulthood. This EEG activity was found in 8 of 14 (57%) adult patients [9] (Fig. 4).

### 4. Differential diagnosis of as EEG

Since none of the EEG abnormalities in AS are in themselves pathognomonic for the syndrome, they may resemble abnormalities seen in other severely retarded patients with or without epileptic seizures. When the AS EEG is seen in the appropriate clinical context, 4p<sup>−</sup> syndrome can be excluded on the basis of the clinical symptoms. EEG findings in 4p<sup>−</sup> syndrome patients are distinct from those in AS patients and show high amplitude spike–wave complexes at 2–3.5 Hz, usually diffuse in bursts and activated by sleep and, 4–6 Hz polyspike–wave complexes in parieto-occipitotemporal regions, often seen only when the eyes are closed [19]. Rett syndrome (RS) is an important differential diagnosis because there can be a phenotypic overlap between AS and RS [20]. In practice, every child with a possible clinical diagnosis of AS and an EEG which is comparable for AS, without genetic abnormalities on genetic testing, should be tested for an MECP2 mutation. The difference between hypsarrhythmia and AS in a very young child might be difficult to distinguish, although in West syndrome periods of suppression are seen in a much more chaotic EEG. Also important is the fact that in AS there are no changes in EEG from the awake to the sleeping state, thus differing from West syndrome. The clinical context of West syndrome with clusters of tonic seizures might be different from that in AS although there have been descriptions of AS patients with a hypsarrhythmic EEG at a young age [6]. The runs of slow waves mixed with epileptiform discharges with anterior predominance may resemble the petit mal variant seen in the Lennox-Gastaut syndrome, a syndrome with a peak age between 3 and 5 years [6,11]. But as mentioned above, EEG

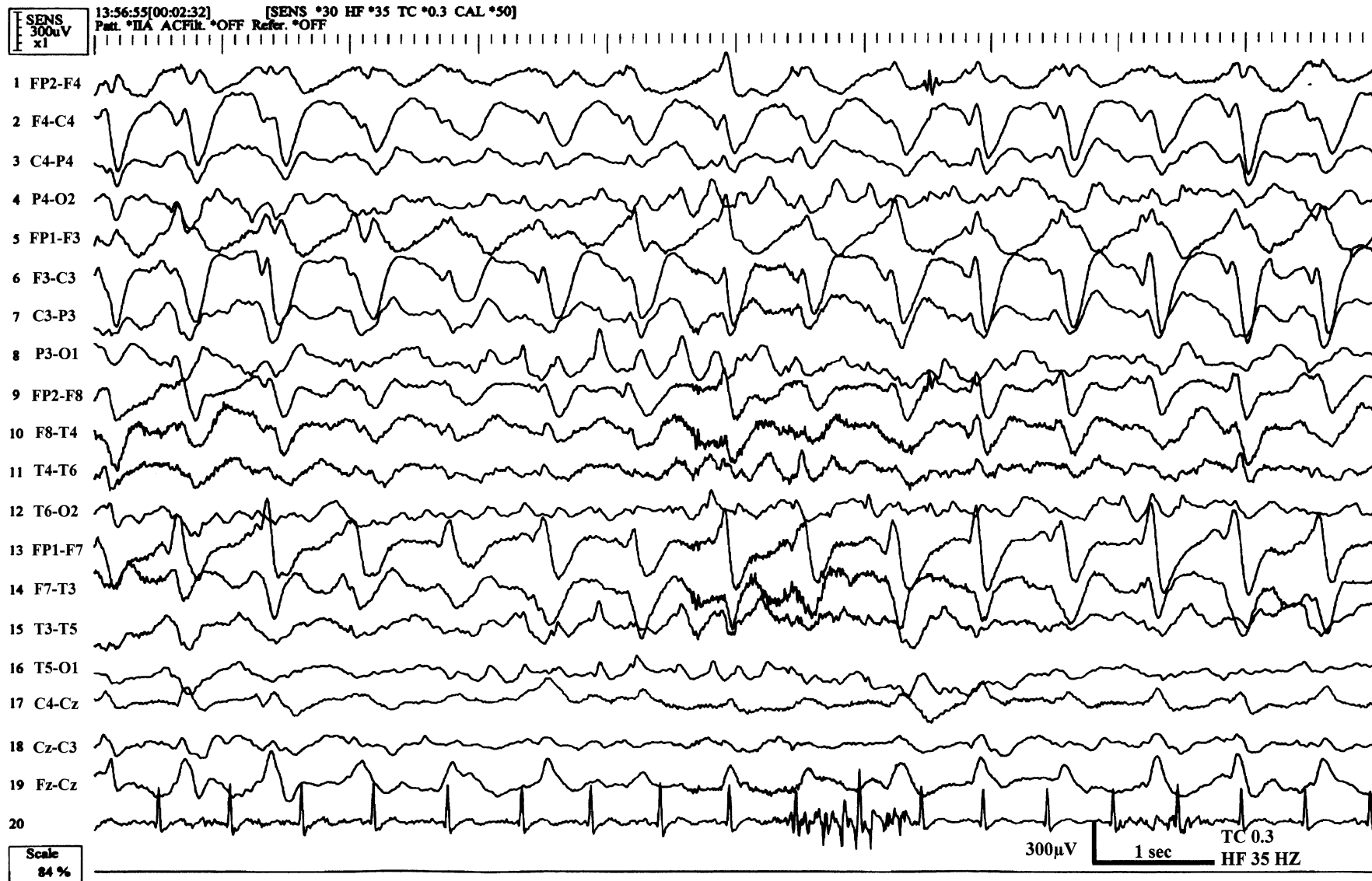


Fig. 4. Rhythmic 1.5–2 Hz activity (triphasic activity) over the frontal regions in a 38-year-old man with AS and a UBE3A mutation.

findings in AS patients may include predominance of slow activity with superimposed epileptiform discharges, which have no well defined features of the slower spike and wave complexes characteristic of Lennox-Gastaut syndrome. Furthermore, there is no evidence of enhancement of epileptiform activity during sleep, which is well defined in Lennox-Gastaut syndrome [4,14].

## 5. Conclusions

We believe that there is a characteristic AS EEG but one has to see the EEG in the appropriate clinical context. Being aware of such EEG patterns can significantly contribute to the possible diagnosis of AS, especially at a young age, and this is important for genetic counselling. There are, however, still patients with typical clinical features of AS but in whom these EEG patterns are not found, although the clinician is suspecting the possibility of this syndrome.

## References

- [1] Angelman H. 'Puppet' children. A report on three cases. *Dev Med Child Neurol* 1965;7:681–8.
- [2] Williams CA, Angelman H, Clayton-Smith J, Driscoll DJ, Hendrickson JE, Knoll JH, et al. Angelman syndrome: consensus for diagnostic criteria. Angelman Syndrome Foundation. *Am J Med Genet* 1995;56:237–8.
- [3] Clayton-Smith J, Laan LAEM. Angelman syndrome: a review of the clinical and genetic aspects. *J Med Genet* 2003;40:87–95.
- [4] Boyd SG, Harden A, Patton MA. The EEG in early diagnosis of the Angelman (happy puppet) syndrome. *Eur J Pediatr* 1988;147:508–13.
- [5] Pampiglione G, Martinez A. Evolution of Angelman syndrome: follow up of 3 new cases. *Electroencephalogr Clin Neurophysiol* 1983;56:72P.
- [6] Matsumoto A, Kumagai T, Miura K, Miyazaki S, Hayakawa C, Yamanaka T. Epilepsy in Angelman syndrome associated with chromosome 15q deletion. *Epilepsia* 1992;33:1083–90.
- [7] Casara GL, Vecchi M, Boniver C, Drigo P, Baccichetti C, Artifoni L, et al. Electroclinical diagnosis of Angelman syndrome: a study of seven cases. *Brain Dev* 1995;17:64–8.
- [8] Buoni S, Grosso S, Pucci L, Fois A. Diagnosis of Angelman syndrome: clinical and EEG criteria. *Brain Dev* 1999;(21):296–302.
- [9] Laan LAEM, Renier WO, Arts WFM, Buntinx IM, vd Burgt IJAM, Stroink H, et al. Evolution of epilepsy and EEG findings in Angelman syndrome. *Epilepsia* 1997;38:195–9.
- [10] Minassian BA, DeLorey TM, Olsen RW, Phillipart M, Bronstein Y, Zhang Q, et al. Angelman syndrome: correlations between epilepsy phenotypes and genotypes. *Ann Neurol* 1998;43:485–93.
- [11] Sugimoto T, Yasuhara A, Ohta T, Nishida N, Saitoh S, Hamabe J, et al. Angelman syndrome in three siblings: characteristic epileptic seizures and EEG abnormalities. *Epilepsia* 1992;33(6):1078–82.
- [12] MacGillivray BB. The EEG in liver disease. In: Rémond A, editor. *Handbook of electroencephalography and clinical neurophysiology*. Amsterdam: Elsevier; 1976. p. 26–50.
- [13] Bickford RG, Butt HR. Hepatic coma: the electroencephalographic pattern. *J Clin Invest* 1955;34:790–9.
- [14] Viani F, Romeo A, Viri M, Mastrangelo M, Lalatta F, Selicorni A, et al. Seizure and EEG patterns in Angelman's syndrome. *J Child Neurol* 1995;10:467–71.
- [15] Zhdanova IV, Wurtman RJ, Wagstaff J. Effects of low dose of melatonin on sleep in children with Angelman syndrome. *J Pediatr Endocrinol Metab* 1999;12:57–67.
- [16] Guerrini R, DeLorey TM, Bonanni P, Moncla A, Dravet C, Suisse G, et al. Cortical myoclonus in Angelman syndrome. *Ann Neurol* 1996;40:39–48.
- [17] Laan LAEM, Halley DJJ, den Boer ATH, Hennekam RCM, Renier WO, Brouwer OF. Angelman syndrome without detectable chromosome 15q11–13 anomaly: clinical study of familial and isolated cases. *Am J Med Genet* 1998;76:262–8.
- [18] Laan LAEM, van den Ouweland AMW, Bakker LPG, Catsman-Berrevoets CE, Halley DJJ. Angelman syndrome: AS phenotype correlated with specific EEG pattern may result in a high detection rate of mutations in the UBE3A gene. *J Med Genet* 1999;36:723–4.
- [19] Battaglia A, Carey JC, Cederholm P, Viskochil DH, Brothman AR, Galasso C. Natural history of Wolf-Hirschhorn syndrome: experience with 15 cases. *Pediatrics* 1999;103:830–6.
- [20] Laan LAEM, Vein AA. A Rett patient with a typical Angelman EEG. *Epilepsia* 2002;43:1590–2.