

# Angelman syndrome: evolution of the phenotype in adolescents and adults

Jill Clayton-Smith MB ChB FRCP FRCPC MD, Consultant Clinical Geneticist, Regional Genetic Service, St. Mary's Hospital, Manchester, M13 OJH, UK.  
E-mail: jcs@central.cmht.nwest.nhs.uk

Individuals with Angelman syndrome (AS) have severe learning disability, \* ataxia, seizures, dysmorphic facies, a happy, sociable disposition, and inability to speak. Most of the literature concerning the clinical features of AS has concentrated on younger children. This study aimed to look at the natural history of AS by documenting the clinical features in a group of 28 adolescents and adults with AS (12 males, 16 females; age range 16 to 40 years). Specific aspects studied included physical characteristics, general health, mobility, seizure disorder, behaviour and communication, and self-help skills. Problems seen in this older group of individuals differed significantly from those typically observed in younger children. The incidence of scoliosis and joint contractures increased with age. Facial features were more striking in adults. Hyperactivity and concentration improved and the sociable disposition persisted. There were subtle clinical differences between the groups of individuals with different underlying genetic abnormalities. Information obtained from this study is relevant to diagnosis and management of older individuals with AS.

In 1965 Harry Angelman described three children with severe learning disability, a seizure disorder with a characteristic EEG, absent speech, ataxic jerky movements, and a happy sociable disposition (Angelman 1965). All three of these children were hypopigmented. This condition is now known as Angelman syndrome (AS) and although it was described relatively rarely until 1987 when the first diagnostic tests for AS became available, it is now thought to have a frequency as high as 1 in 10- to 20 000 (Petersen et al. 1995). The features of AS usually become apparent at a few months of age because of delay in motor milestones, ataxic jerky movements, and onset of seizures. There have been several good clinical reviews of AS (Williams and Frias 1982, Robb et al. 1989, Zori et al. 1992, Clayton-Smith 1993) but these have concentrated mainly on the clinical features in younger patients. Bjerre reported a 76-year-old patient from Sweden in 1984 and more recently others have published further clinical details of adults with AS (Williams et al. 1989, Buntinx et al. 1995, Reish et al. 1995, Laan et al. 1996, Sandanam et al. 1997). Some reports have been of single patients and the majority have concerned adults who have lived for a great part of their life in large institutions. This study aimed to document the evolution of the clinical features and natural history of AS in a population of young adults who had for most of their life lived at home with their parents or in smaller group homes. Results of these observations should give a more accurate picture of what the future may hold for the current cohort of children with AS.

The genetic mechanisms giving rise to AS are complex. Several different genetic mechanisms, all involving 15q11-13 are known to give rise to the Angelman phenotype. These have recently been reviewed by Jiang and colleagues (1999). The majority of patients (70 to 75%) have a deletion of chromosome 15q11-13 which is of maternal origin. Other patients have paternal uniparental disomy of chromosome 15, a defect in the imprinting process involving the 15q11-13 region or a mutation in the UBE3A gene at this locus. A group of patients remain in whom no genetic abnormality has been identified. As more patients are studied, subtle clinical differences are emerging between groups of patients with different genetic abnormalities (Smith et al. 1996, Moncla et al. 1999, Saitoh et al. 1999). This study, therefore, sought to correlate the clinical findings with the specific genetic abnormalities found.

## Method

The study group comprised 28 individuals with AS, (12 males, 16 females) whose ages ranged between 16 and 40 years. Of these, 15 had originally been ascertained as part of a UK clinical study carried out between 1989 and 1991 (Clayton-Smith 1993) and had been followed up subsequently. The remaining individuals were seen personally by the author between 1995 and 1999. A detailed history was collected from the parents or carers of each individual and supplemented with information from medical notes. Clinical features of each individual were also documented. In all cases, genetic analysis of chromosome 15q11-13 had been carried out. The genetic mechanism giving rise to AS had been identified in each patient.

## CLINICAL FINDINGS

General health was good in 23 of the 28 participants. Two of the remaining patients were incapacitated by severe seizures,

\*UK usage. US usage: mental retardation.

which were difficult to control. A further patient had severe reflux oesophagitis with a stricture requiring surgery. The final two patients, both of whom had limited mobility and severe scoliosis, also had undernutrition and respiratory compromise. One of these had a history of prolonged seizures as a child resulting in a cerebral infarction. In the group as a whole, the main medical problems documented were seizures which were present in 11 individuals and oesophageal reflux which was present in 12 participants but severe in three. Ten patients had developed scoliosis with curvature of the spine often becoming apparent during the adolescent growth spurt. In the majority of individuals, growth parameters were within the normal range, although heights tended to be slightly reduced compared to other family members. Nine individuals had become very obese during their teenage years. Seven of this group were females. A major cause of this obesity was immobility and lack of exercise, although the fact that most individuals with AS have a good appetite probably contributed also. None of the participants displayed true hyperphagia as one might see in Prader-Willi syndrome (Butler et al 1986). Only seven patients were free of all of the complications listed above, but in 16 of the others the problems were mild, consisting of an occasional seizure or scoliosis which had been corrected by surgical treatment.


Facial features in every case had changed over time due to elongation of the face. The deep-set eyes and prominent chin often seen in younger children with AS became more obvious in adulthood (Figs 1 and 2). Faces tend to be less round, but did not tend to coarsen excessively with age. All participants had gone through puberty at the normal time and developed

normal secondary sexual characteristics. Menstruation was generally regular and several women experienced premenstrual symptoms. Masturbation was reported in the majority of patients, and if inappropriate could be successfully managed by behaviour modification e.g. encouraging individuals to do this in private. Libido appeared to be quite low. None of the study group had had sexual intercourse or used contraceptives, although their sociable disposition is likely to make them very vulnerable to approaches from others.

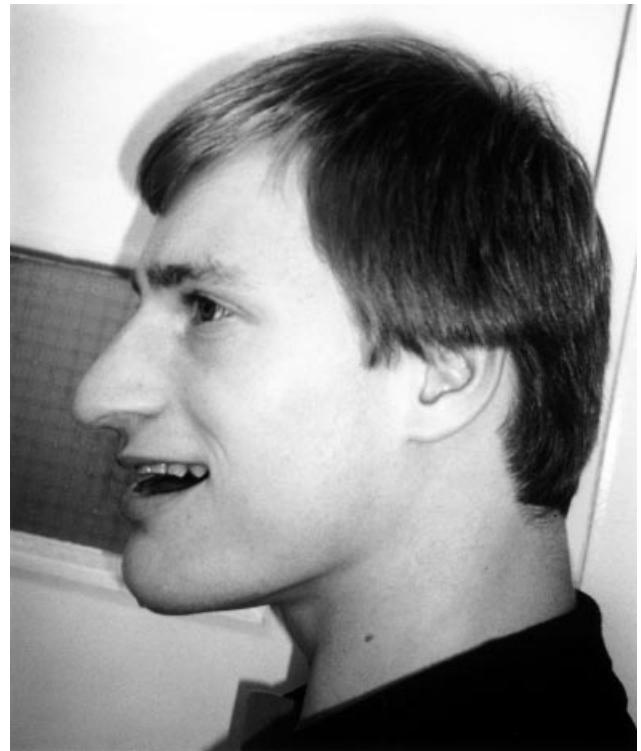
Mobility decreased in all patients over the years as the hyperactivity of childhood gave way to a reluctance to exercise and resultant increased weight gain. The presence of hypertonicity in the limbs led to the development of contractures of the large joints and a characteristic stooped posture (Fig. 3). Mobility was also affected by the development of scoliosis (Fig. 4). Three of the 10 patients with scoliosis underwent major corrective surgery with complete success and the procedure had been well tolerated. Scoliosis was progressive in the patients who had not had surgery.

There was a change in the frequency of seizures in older patients. After a relatively quiescent phase in the teenage years, eight of 28 patients experienced an increase in seizure frequency during their mid-twenties, and once again the seizures became difficult to control. Myoclonic seizures and generalized tonic-clonic seizures were most common. Several of the women appeared to have more seizures perimenstrually.

All of the adults seen continued to have characteristic happy, sociable behaviour for most of the time. Other behaviours observed were anxiety and episodes of aggression, especially if there was a disruption in routine or a change of carers. Inability to indicate basic needs was thought to be the



**Figure 1:** Facial features in young adult with Angelman syndrome. Note open mouth and prominent chin.



**Figure 2:** Profile of 26-year-old man demonstrating microcephaly, deep-set eyes, and prominent chin.

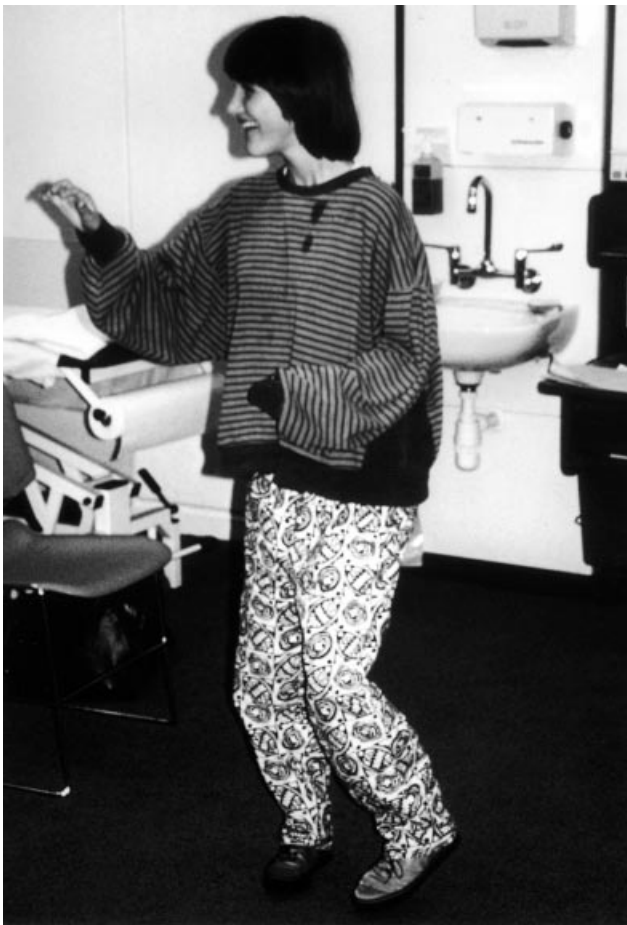
cause of the aggressive tendencies in some patients as those with better communication seemed to have less problems.

The ataxic gait, which is one of the hallmarks of AS in childhood, was present in the adults but was less obvious because they were not so active. Seven individuals had a worsening tremor. In two patients the tremor was very severe, and compromised their ability to feed themselves. Hyperactivity was reduced and concentration span improved with age. Watching TV and videos were popular pastimes. Adolescents and adults did not have the poor sleep pattern seen in younger children. The love of water, which is typical of AS in younger children persisted. In almost every case, the parents and carers of adults with AS thought that management on a day-to-day basis was easier than in childhood because of the improvement in hyperactivity.

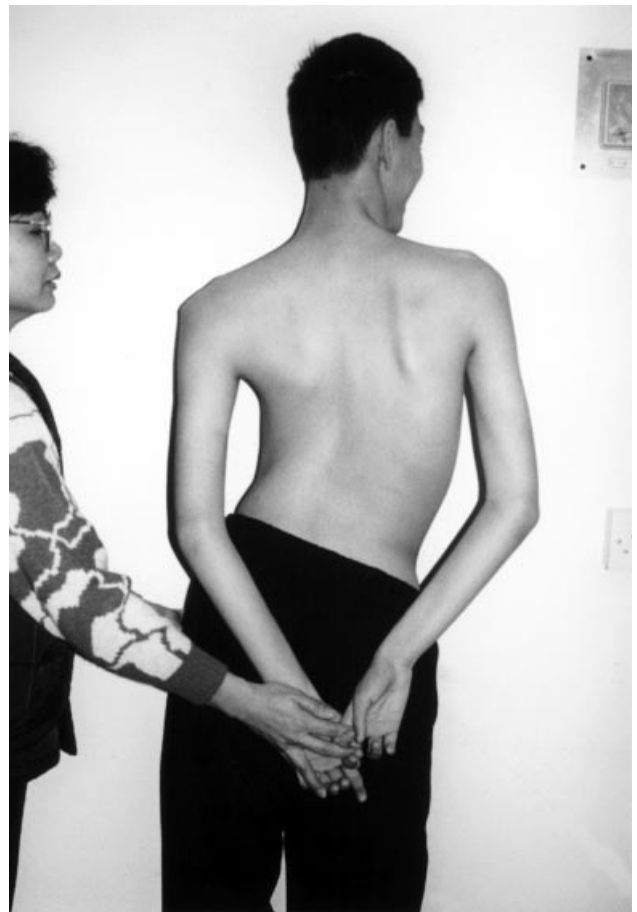Communication skills improved with progress towards adulthood, and this was attributed to an improvement in concentration span. None of the people with AS studied were able to say more than two or three words, even with intensive speech therapy, apart from one individual who had uniparental disomy. Nineteen of the 28 individuals, were able to communicate their basic needs. The majority used gestures for communication, although three were proficient at signing and one young woman who used an augmented

communication device was able to recognise around 200 symbols. Communication skills were easily lost if they were not constantly reinforced.

There was a great variation in self-help skills across the group studied. All individuals required supervision. Of the 28 participants, 21 were able to walk and 20 could feed themselves; 20 were dry by day but 25 of 28 needed to wear nappies at night; 17 could carry out simple household tasks. All required assistance with washing but around 14 could dress and undress if the fastenings on the clothes were simple. The majority were able to make simple choices e.g. of what food they would like to eat and what clothes they would like to wear. They were able to indicate likes and dislikes but lacked conceptual thinking and had no sense of danger. None were able to manage money or negotiate roads safely on their own. In general, the young adults fitted into their local communities well and were very sociable. Several were able to swim independently and others enjoyed a range of pursuits including horse riding, bowling, and acting with a theatre group. Three adults had jobs, which they carried out under supervision. These included delivering newspapers, cleaning, and helping in a shop. The main problem the individuals experienced with working was their inability to stay focused, so that constant supervision was needed. Residential arrangements



**Figure 3:** *Young adult with Angelman syndrome demonstrating characteristic posture with upheld arms and flexion at hips and knees.*



**Figure 4:** *Scoliosis developing over a 2-year period during adolescent growth spurt.*

varied. Fifteen individuals were still living at home. Two, who were both under 19 years of age, were at residential schools during term time. One had moved as an adult into a relatively large institution and nine lived in group homes within the local community where integration was usually good. The remaining patient, who was 38 years old at the time of examination, was the first patient reported by Harry Angelman in his 1965 paper. She was resident temporarily in a hospital, but had been cared for until that time by her mother.

#### IMPLICATIONS OF THE STUDY

This study demonstrates that the clinical features of AS in adolescents and adults differ from those seen in younger children. Although the happy, sociable disposition remains a constant feature, there are changes in the physical appearance and behavioural features with age. Some of the complications seen in adults such as joint contractures and scoliosis develop over a period of time and if anticipated can be effectively treated at an early stage. In some cases physiotherapy or bracing will be sufficient to resolve scoliosis, but in other individuals it progresses relentlessly despite treatment with these conservative measures and major surgery is required. This is tolerated surprisingly well and usually results in an improvement in overall mobility. Mobility is commonly lost in adults and can be improved by physiotherapy which can be carried out by both parents and professionals. Encouraging activity and maintaining a full range of movement of the joints is helpful in preventing the development of contractures. Dietary control and encouraging exercise can minimize obesity which is a particularly common feature in women with AS. Communication therapy should still be pursued with adolescents and young adults as at this stage concentration has begun to improve and they appear to be more receptive to learning than young children with AS. Seizures may return in adulthood and this should be borne in mind if there is any unexpected deterioration in health or behaviour. As with younger children, sodium valproate and clonazepam appear to be most beneficial in the treatment of seizures. Laan and coworkers (1996) also found phenobarbitone useful. Finally, oesophageal reflux can be severe in adults with AS. It may be difficult to diagnose because of the communication problems present and should be suspected in individuals who lose their appetite, develop feeding problems, or become inexplicably distressed.

#### Discussion

This study documents clinical findings in a group of older individuals with AS, suggesting that the phenotype differs in older patients and that long-term complications often develop. Although the numbers were small, a correlation was observed between the abilities of the individuals we studied and the genetic mechanisms giving rise to AS. There was only one patient with uniparental disomy, one with an imprinting defect, seven with UBE3A mutations and 19 with deletions of 15q11-13. The individual with uniparental disomy had significantly increased mobility and better speech than the remaining patients and did not have seizures. The patient with an imprinting mutation had good communication skills, was not hypopigmented and had less typical facial features of AS. Of the 19 individuals with chromosome 15 deletions, all had typical characteristics of AS including dysmorphic facies and hypopigmentation. Seizures and lack of mobility

were common within this group. The group with UBE3A mutations, which included five familial and two sporadic individuals, were again typical but they were not hypopigmented and their mobility was better than the deletion group. Characteristic EEG findings were seen in individuals from all groups, but not in every patient. In patients where serial EEGs had been carried out the abnormalities did change with age, and were more difficult to detect in older patients. Laan and colleagues (1996) suggested that the most common abnormality seen in adult EEGs is a rhythmic triphasic two to three cycles per second delta activity of high voltage, especially over the frontal regions, rather than the four to six cycles per second slow-wave activity described in paediatric patients by Boyd and colleagues (1988). This feature was not specifically looked for in many of the EEGs from this series of patients.

Some of these clinical findings can now be interpreted in the light of our current knowledge of the molecular genetics of AS; patients with deletions have only a single copy of the P gene, a recessive gene known to cause Type II oculocutaneous albinism, and this is likely to be related to the hypopigmentation seen in this group (Spritz et al. 1997). Typical AS deletion is of a large size, approximately 4 kb of DNA. It is thus likely that other genes with this 4 kb region, as well as the UBE3A gene which is critical for AS, will be absent. This would explain the more severe phenotype seen in patients with a deletion. The fact that point mutations within the UBE3A gene give rise to a typical clinical picture suggest that it is this gene which is the most important in production of the Angelman phenotype.

In summary, this study furthers our knowledge of the natural history of AS and offers parents and carers of young children with AS some insight into the problems which may be experienced in later years and how they may be managed. Although complications develop in the majority of individuals, many of these are mild and do not have a major effect on quality of life. There is a suggestion that the movement disorder, particularly tremor, may be progressive in a minority of patients. Further studies of mouse models of AS may help to explain the biological basis behind this observation.

*Accepted for publication 20th December 2000.*

#### Acknowledgements

I would like to acknowledge the help of ASSERT, a UK support group for Angelman syndrome and the help of families involved in this study.

#### References

- Angelman H. (1965) 'Puppet' children. A report on three cases. *Developmental Medicine & Child Neurology* 7: 681-8.
- Bjerre I, Fagher B, Ryding E, Rosen I. (1984) The Angelman or 'happy puppet' syndrome. Clinical and electroencephalographic features and cerebral blood flow. *Acta Paediatrica Scandinavica* 73: 398-402.
- Boyd SG, Harden A, Patten MA. (1988) The EEG in early diagnosis of the Angelman (happy puppet) syndrome. *European Journal of Paediatrics* 147: 508-13.
- Buntinx IM, Hennekam RCM, Brouwer OF, Stroink H, Beuten J, Mangelschots K, Fryns JP. (1995) Clinical profile of Angelman syndrome at different ages. *American Journal of Medical Genetics* 56: 176-83.
- Butler MG, Meaney FJ, Palmer CG. (1986) Clinical and cytogenetic survey of 39 individuals with Prader-Labhart-Willi syndrome. *American Journal of Medical Genetics* 23: 793-809.
- Clayton-Smith J. (1993) Clinical research on Angelman syndrome in the United Kingdom: observations on 82 affected individuals. *American Journal of Medical Genetics* 46: 12-5.

- Jiang Y, Lev-Lehman E, Bressler J, Ting-Fen T, Beaudet AL. (1999) Genetics of Angelman Syndrome. *American Journal of Human Genetics* **65**: 1–6.
- Laan LAEM, den Boer AT, Hennekam RCM, Renier W, Brouwer OF. (1996) Angelman syndrome in adulthood. *American Journal of Medical Genetics* **66**: 356–60.
- Moncla A, Malzac P, Voelckel MA, Auquier P, Girardot L, Mattei MG, Philip N, Mattei JF, Lalande M, Livet MO. (1999) Phenotype-genotype correlation in 20 deletion and 20 non-deletion Angelman syndrome patients. *European Journal of Human Genetics* **7**: 131–9.
- Petersen MB, Brondom-Nielson K, Hansen LK, Wulff K. (1995) Clinical, cytogenetic and molecular diagnosis of Angelman syndrome: estimated prevalence rate in a Danish county. *American Journal of Medical Genetics* **60**: 261–2.
- Reish O, King RA. (1995) Angelman syndrome at an older age. *American Journal of Medical Genetics* **57**: 510–11.
- Robb SA, Pohl KRE, Baraitser M, Brett EM. (1989) The 'happy puppet' syndrome of Angelman: review of the clinical features. *Archives of Disease in Childhood* **64**: 83–6.
- Saitoh S, Wada T, Kuno T, Kim KC, Ohashi H, Hashimoto K, Niikawa N. (1999) Clinical characteristics of Angelman syndrome patients with a non-IC-deleted imprinting mutation. *Clinical Genetics* **55**: 277–88.
- Sandanam T, Beange H, Robson L, Woolnough H, Buchholz T, Smith A. (1997) Manifestations in institutionalised adults with Angelman syndrome due to deletion. *American Journal of Medical Genetics* **70**: 415–20.
- Smith A, Wiles C, Haan E, McGill J, Wallace G, Dixon J, Selby R, Colley A, Marks R, Trent RJ. (1996) Clinical features in 27 patients with Angelman syndrome resulting from DNA deletion. *American Journal of Medical Genetics* **33**: 107–12.
- Spritz RA, Bailin T, Nicholls RD, Lee ST, Park SK, Mascari MJ, Butler MG. (1997) Hypopigmentation in the Prader-Willi syndrome correlates with P gene deletion but not with the haplotype of the hemizygous P allele. *American Journal of Medical Genetics* **71**: 57–62.
- Williams CA, Frias JL. (1982) The Angelman ('Happy Puppet') syndrome. *American Journal of Medical Genetics* **11**: 453–60.
- Gray BA, Hendrickson JE, Stone JW, Cantu ES. (1989) Incidence of 15q deletions in the Angelman syndrome: a survey of twelve affected persons. *American Journal of Medical Genetics* **32**: 339–45.
- Zori RT, Hendrickson J, Woolven S, Whidden EM, Gray B, Williams CA. (1992) Angelman syndrome: clinical profile. *Journal of Child Neurology* **7**: 270–80.